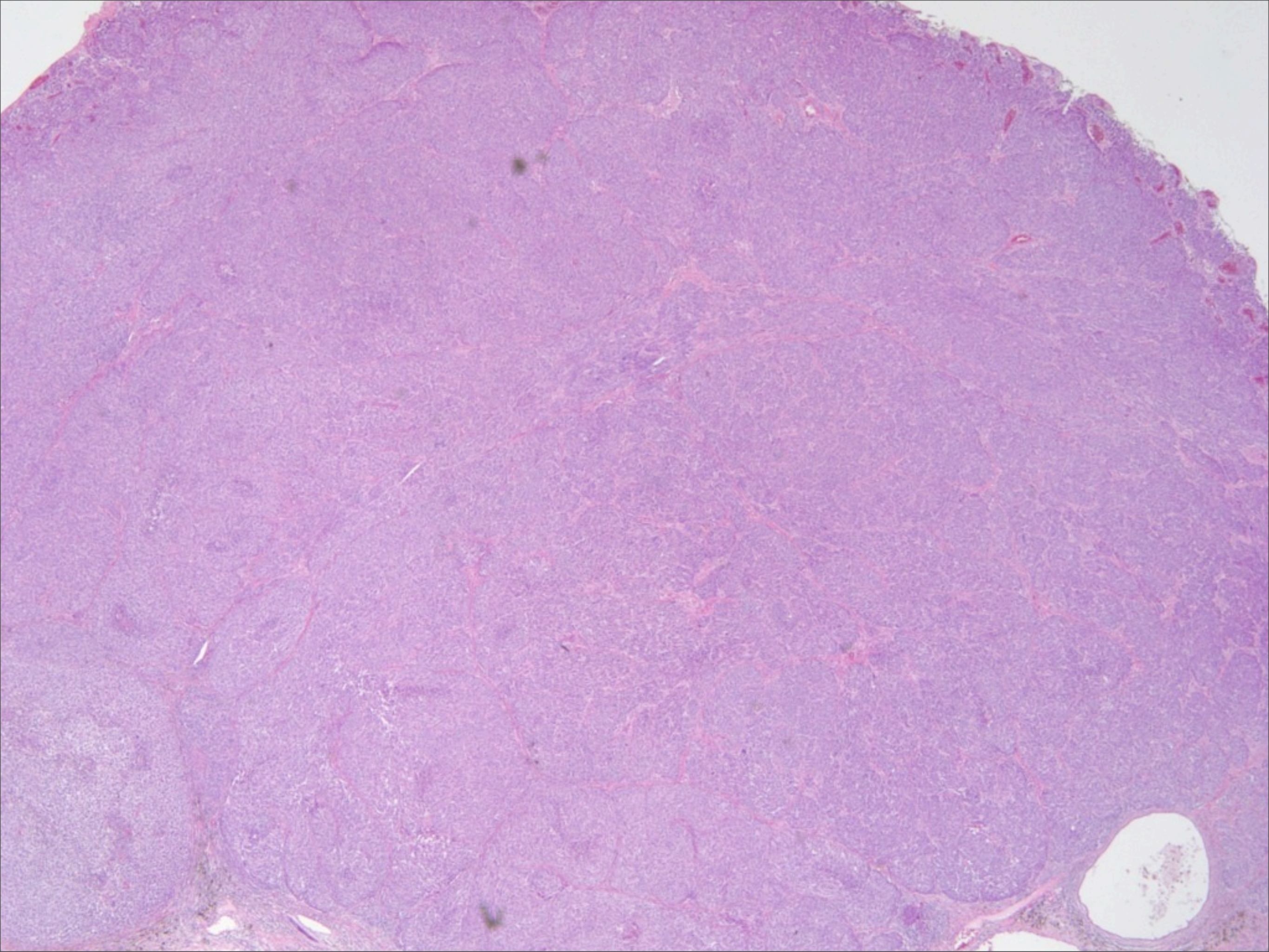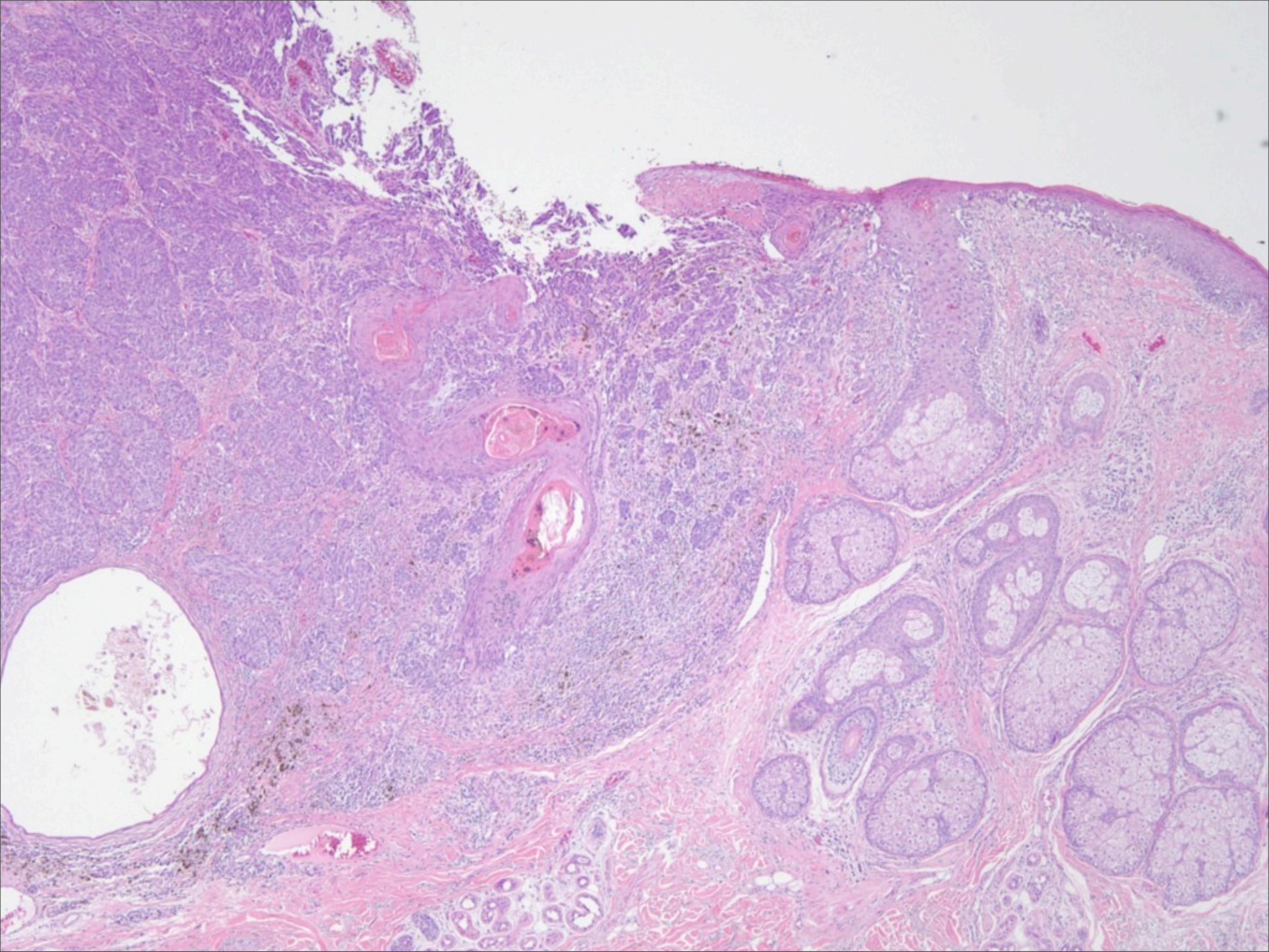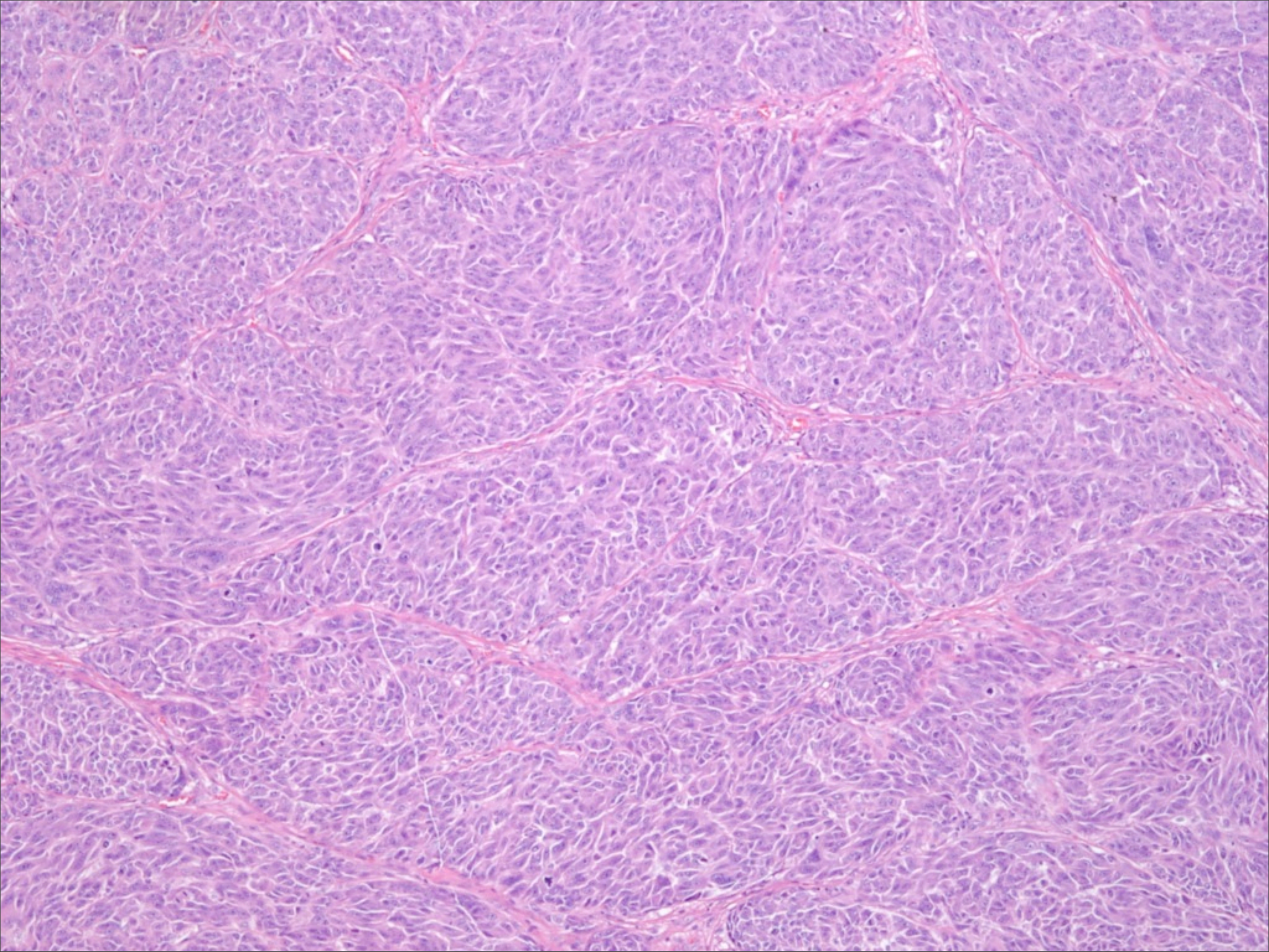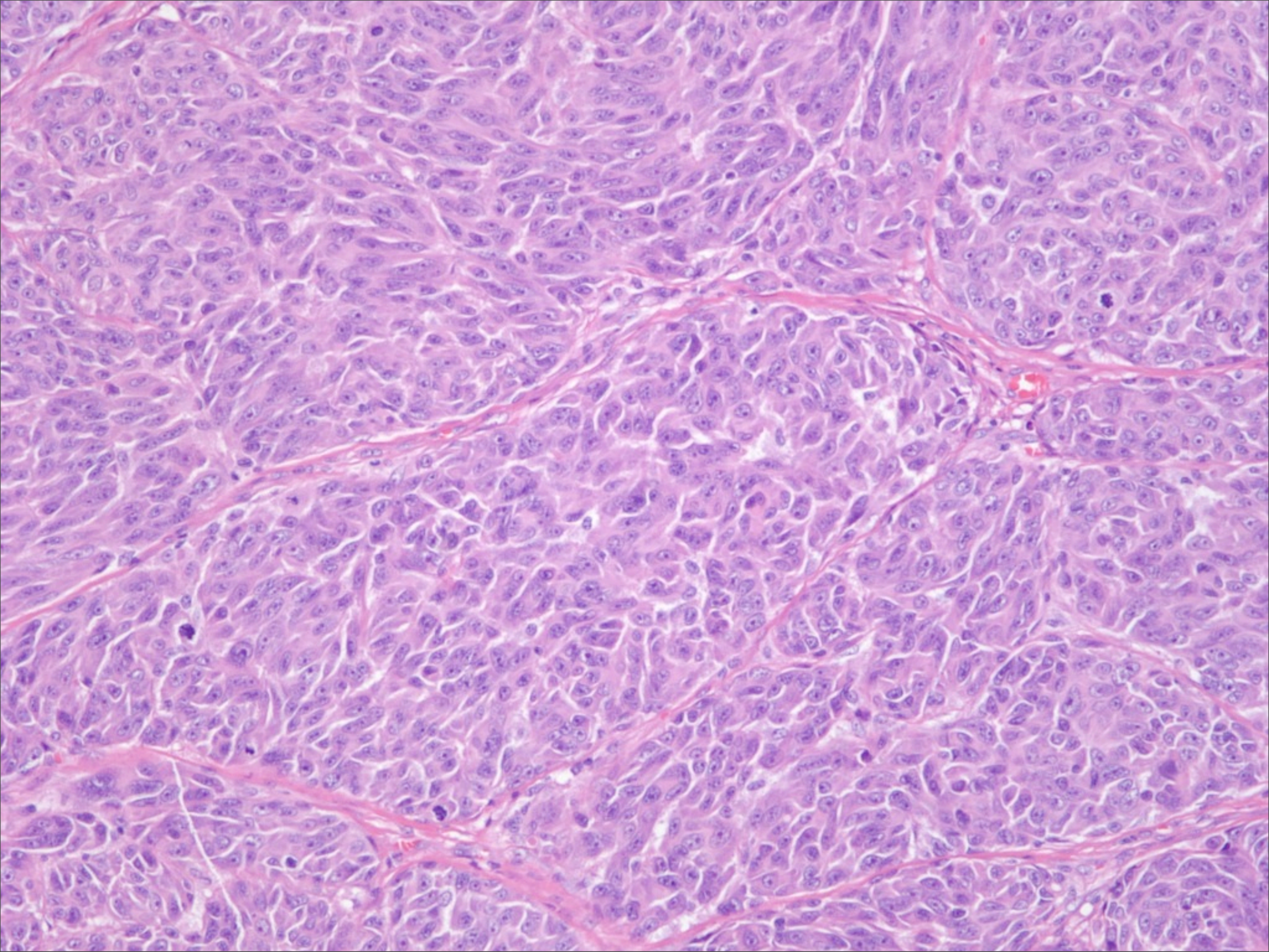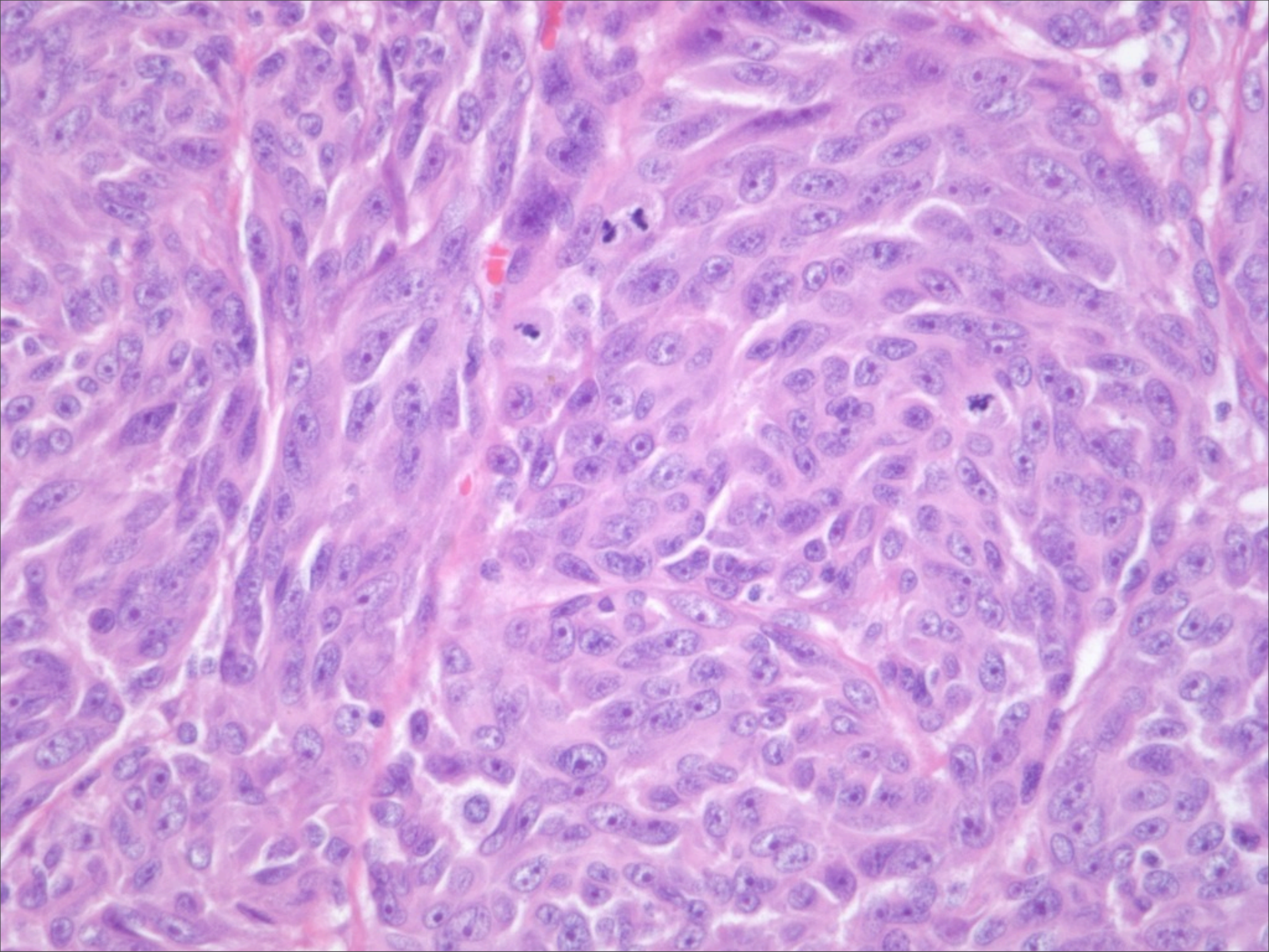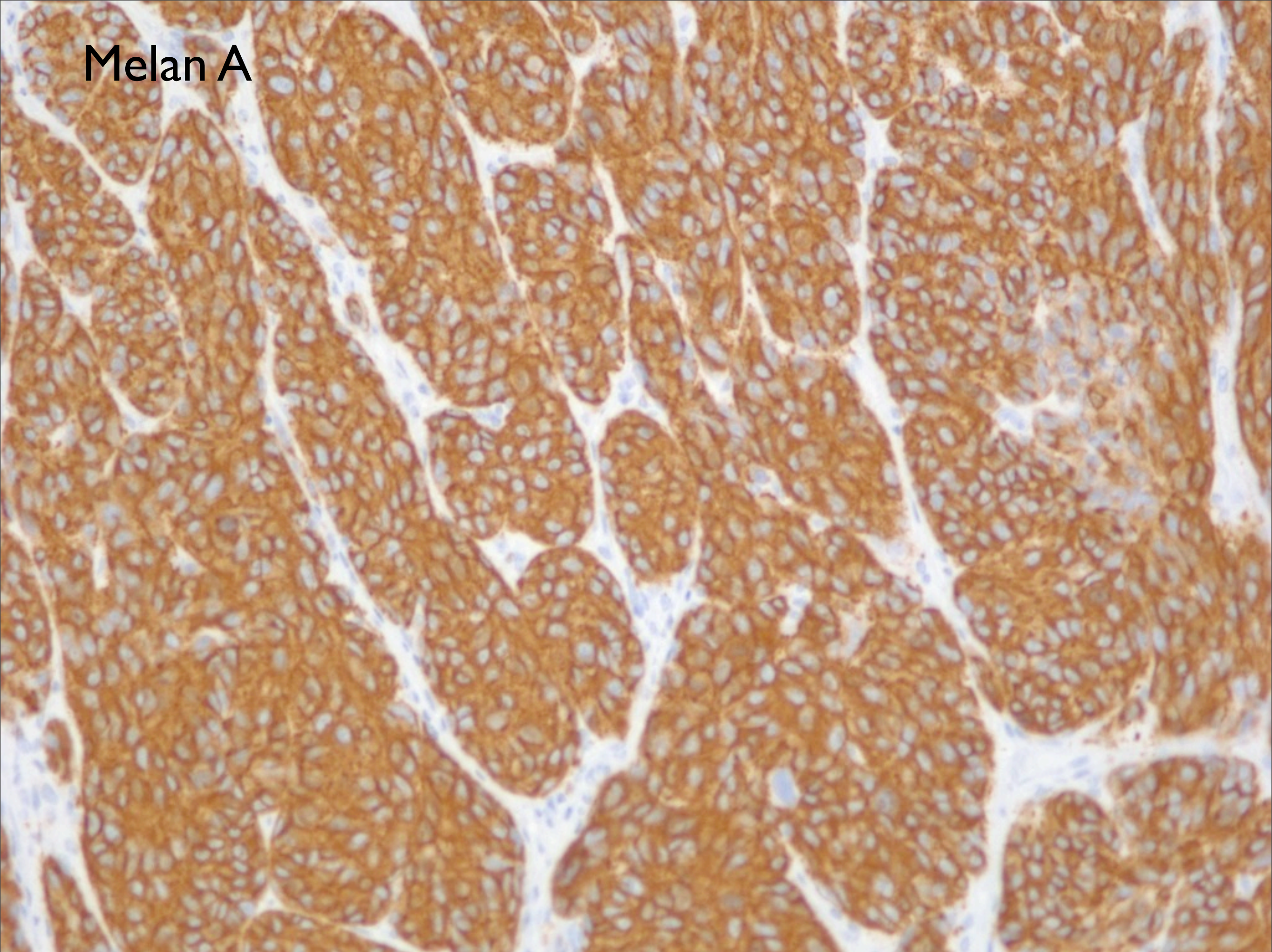
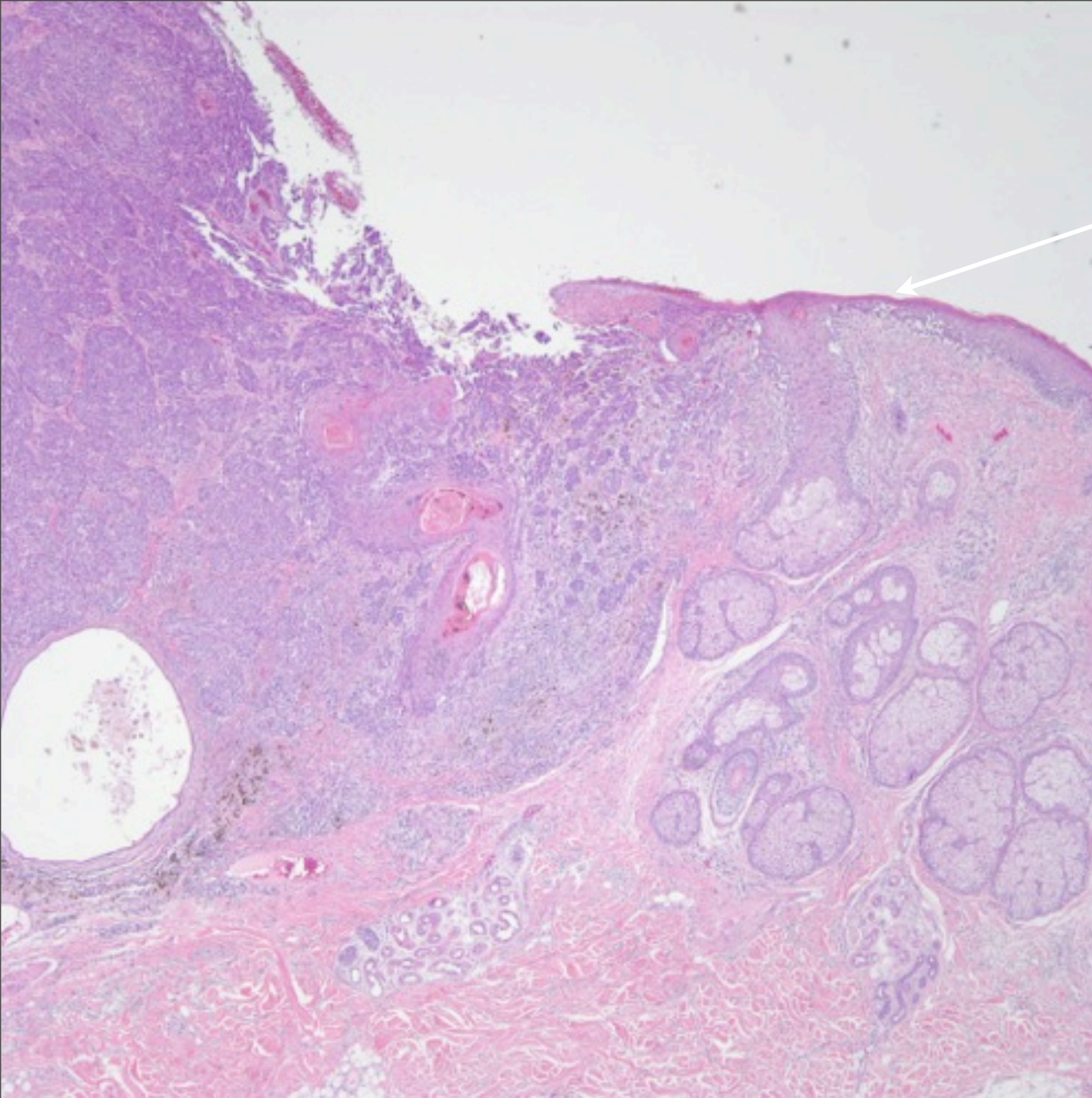


Melan A



Amelanotic Malignant Melanoma



Look for a radial
growth phase

Confirm with Immunostains

Pleomorphic Cells in Sheets and Nests